





# Hair

cuticle

---

---

---

---

---

---

---



cortex

---

---

---

---

---

---

---

# Hair

medulla



# The Hypodermis


# Nerves of the Dermis

free nerve endings \_\_\_\_\_  
\_\_\_\_\_

Meissner's corpuscles \_\_\_\_\_  
\_\_\_\_\_

hair follicle receptor \_\_\_\_\_  
\_\_\_\_\_

pacinian corpuscles \_\_\_\_\_  
\_\_\_\_\_

# Nails

---

---

---

---

---

---

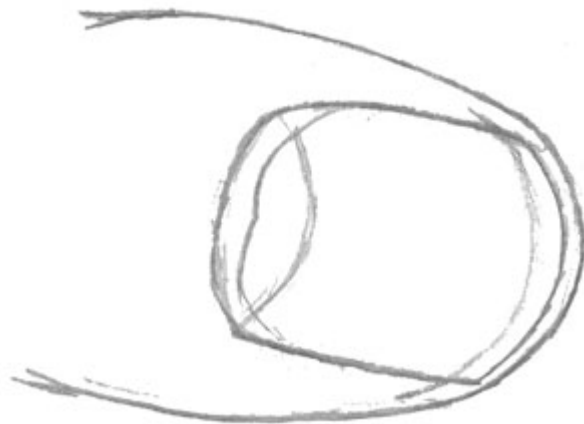
---

---

Nails are good for...

Label the Nail

cuticle  
lunula  
nail fold



Illustrate and diagram the layers of the skin.



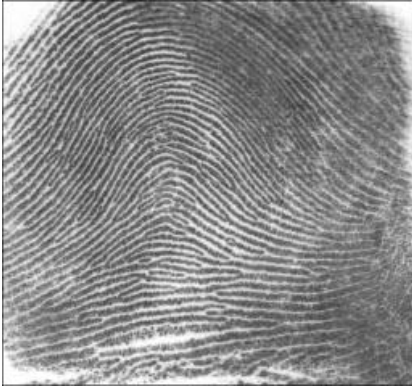hair follicles  
nerves  
epidermis  
dermis

hypodermis  
sweat glands  
blood vessels  
arrector pili

oil glands

# My Fingerprints

**Arch**



**Loop**



**Whorl**



Using a stamp pad, make impressions of your fingers.

<b>Left Pinky</b>	<b>Left Ring</b>	<b>Left Middle</b>	<b>Left Index</b>	<b>Left Thumb</b>
-------------------	------------------	--------------------	-------------------	-------------------

<b>Right Thumb</b>	<b>Right Index</b>	<b>Right Middle</b>	<b>Right Ring</b>	<b>Right Pinky</b>
--------------------	--------------------	---------------------	-------------------	--------------------