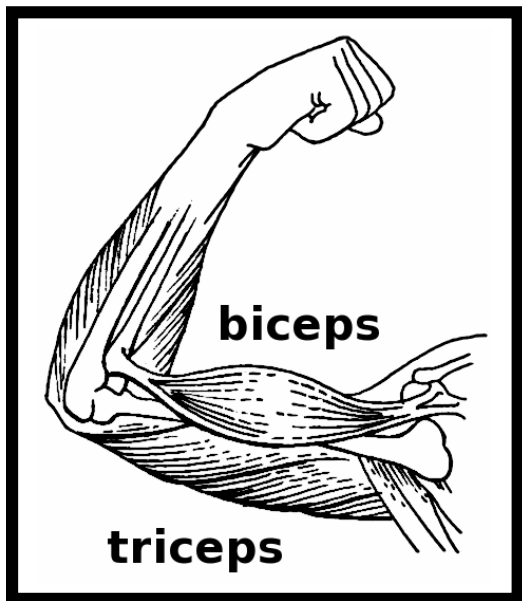


# Muscular System



---

---

---

---

---

---

---

---

---

---

---

---

---

---

---

---

---

---

---

---

---

---

---

---

---

---

---

---

---

---

---

---

---

---

---

---

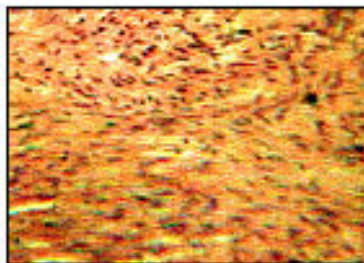
---

---

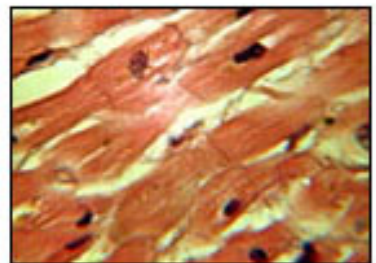
# Types of Muscle



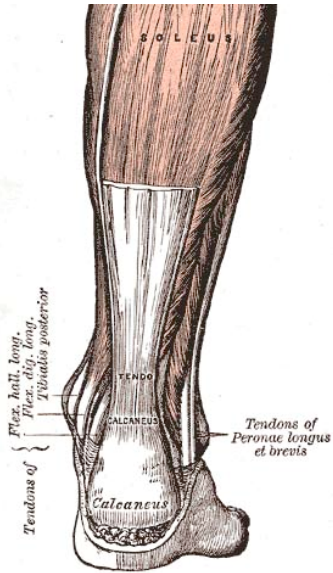
Skeletal muscle



Smooth muscle



Cardiac muscle




---

---

---

---

---

---

---

---

---

---

---

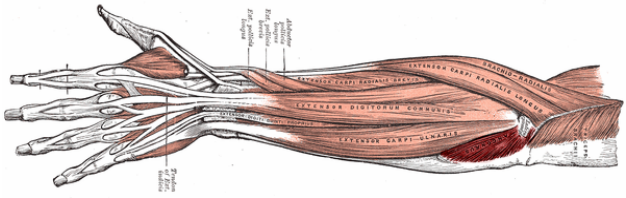


---

---

---

---




---

---

---

---

---

---

---

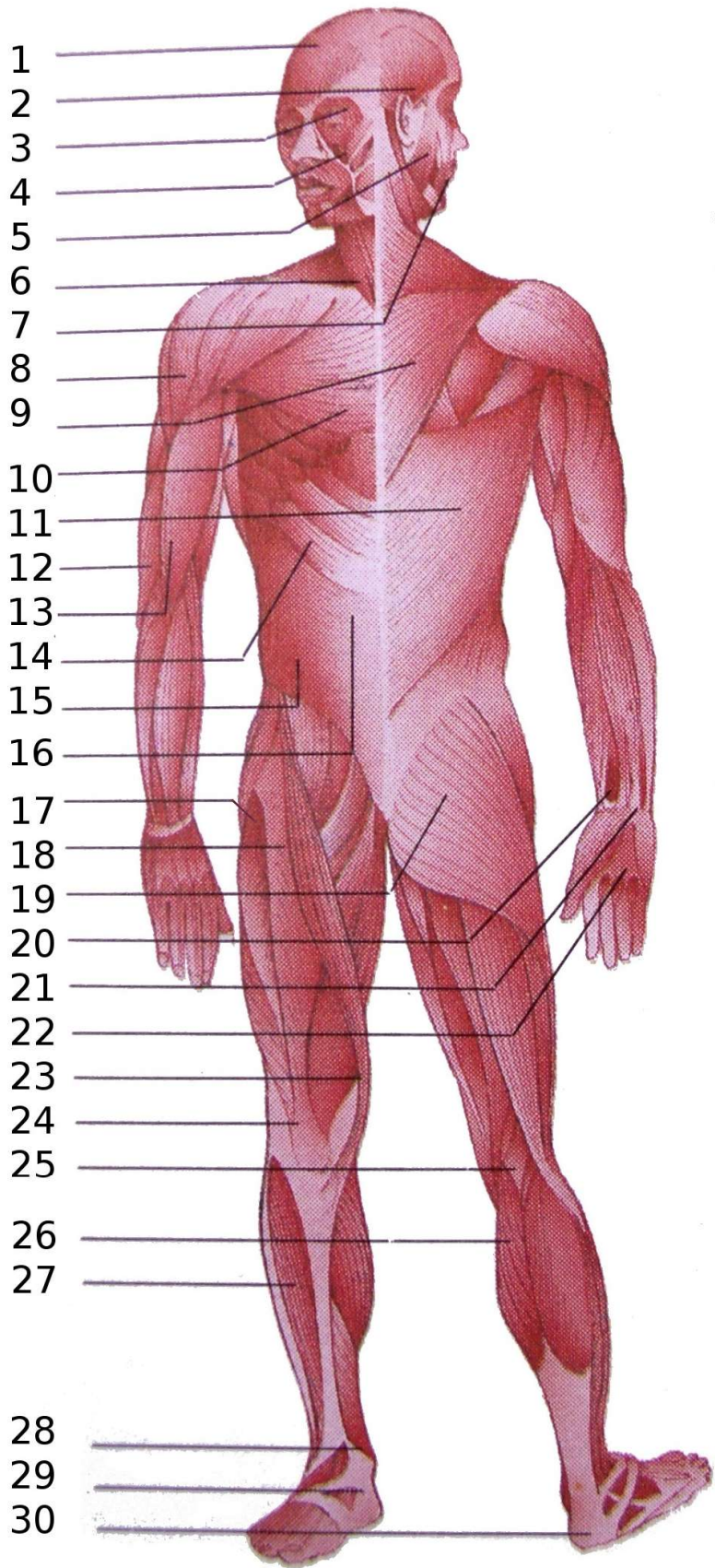
---

---

---

---

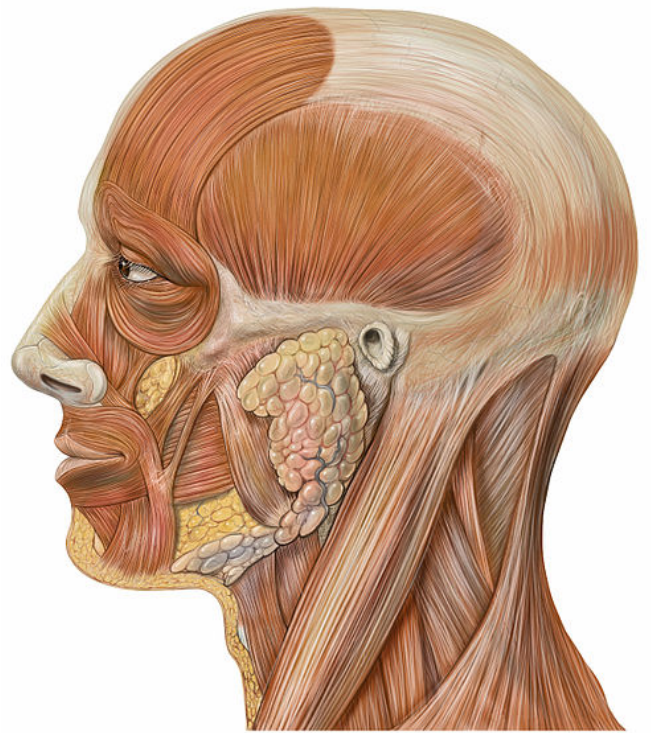
# Skeletal muscles



## Musculus ...

- 1:occipitofrontalis
- 2:temporoparietalis
- 3:orbicularis oculi
- 4:levator labii superior
- 5:masticatorii
- 6:sternocleidomastoideus
- 7:orbicularis oris
- 8:deltoideus
- 9:trapezius
- 10:pectoralis major
- 11:latissimus dorsi
- 12:triceps brachii
- 13:biceps brachii
- 14:serratus anterior
- 15:rectus abdominis
- 16:obliquus externus abdominis
- 17:tensor fascia lata
- 18:rectus femoris
- 19:gluteus maximus
- 20:pronator quadratus
- 21:flexor retinaculum
- 22:flexor digitorum communis
- 23:sartorius
- 24:quadriceps femoris
- 25:ischiocrurale
- 26:gastrocnemius
- 27:tibialis anterior
- 28:soleus
- 29:extensor retinaculum
- 30:triceps surae

# FACIAL MUSCLE



---

---

---

---

---

---

---

---

---

---

---

---

---

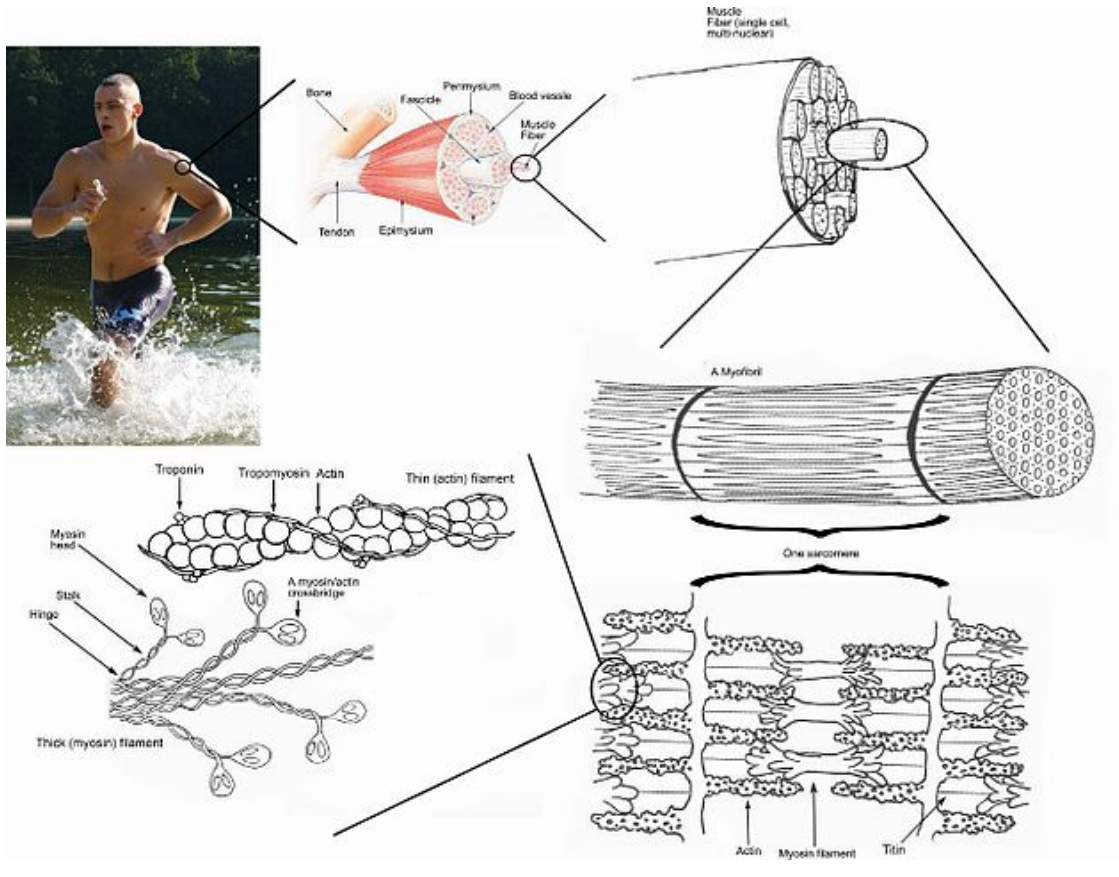
---

---

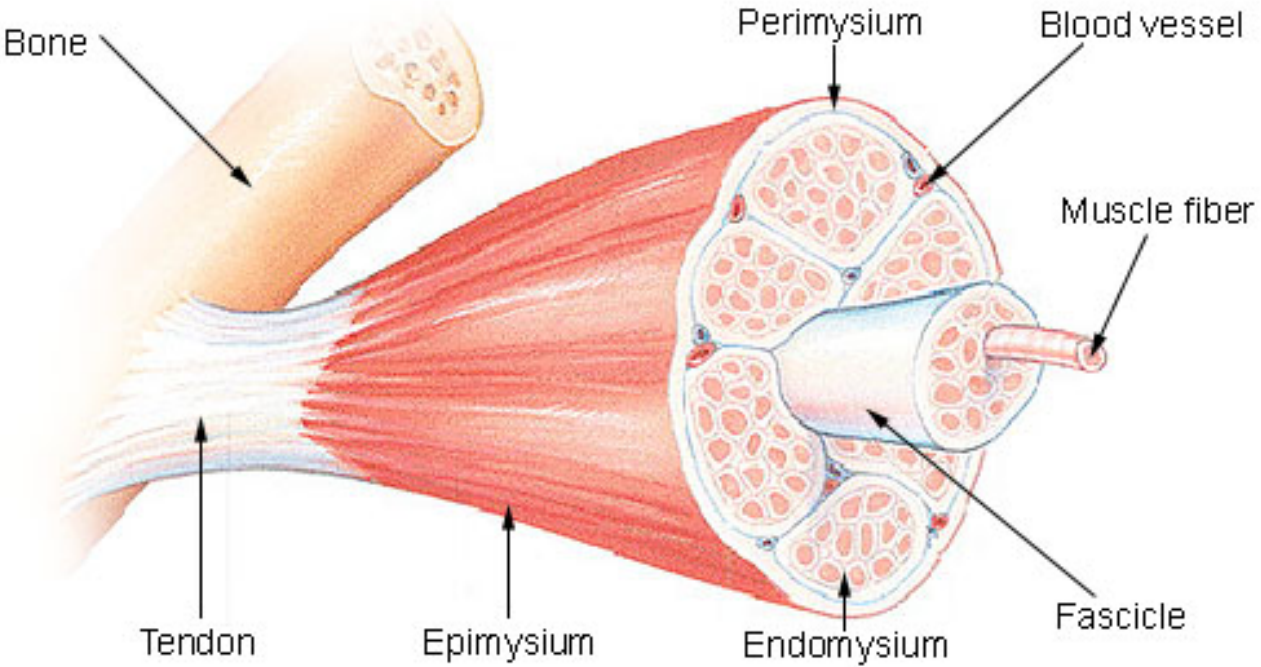
---

---

---



# Structure of a Skeletal Muscle



---

---

---

---

---

---

---

---

---

---

---

---

---

---

---

---

---

---

---

---

---

---

A series of horizontal lines for writing.